Anomalous Cerebral Structure in Dyslexia Revealed With Magnetic Resonance Imaging

Christiana M. Leonard, PhD; Kytja K. S. Voeller, MD; Linda J. Lombardino, PhD; Mary K. Morris, PhD; George W. Hynd, EdD; Ann W. Alexander, MD; Helen G. Andersen, PhD; Mary Garofalakis, MA; Janice C. Honeyman, PhD; Jintong Mao, PhD; O. Frank Agee, MD; Edward V. Staab, MD

• ***Objective.***—**To develop quantitative methods for identifying cerebral anomalies on magnetic resonance images of subjects with language disorders and other learning disabilities.**

Design.—**Partially blinded comparison of subjects with dyslexia, unaffected relatives, and a control group balanced for age and socioeconomic status. Criterion standard: clinical diagnosis of dyslexia by physician or learning disabilities specialist on the basis of clinical assessment and family history.**

Settings.—**Hospital pediatric neurology clinic and private reading clinic.**

Patients and Other Participants.—**Volunteers: individuals with dyslexia (seven male and two female, aged 15 to 65 years) from professional families; unaffected first- and second-degree relatives (four male and six female, aged 6 to 63 years) available in the geographical area; and controls (five male and seven female, aged 14 to 52 years).**

Interventions.—**Gradient echo three-dimensional scan in Seimens 1-Tesla Magnetom; 128 1.25-mm consecutive sagittal images.**

Main Outcome Measures.—**(1) Average length of the temporal (T) and parietal (P) banks of the planum temporale; (2) interhemispheric coefficients of asymmetry for T and P banks: Left-Right interhemispheric coefficients of asymmetry= (L−R)/[(L+R)/2]; (3) intrahemispheric coefficients of asymmetry=(T−P)/[(T+P)/2]; and (4) qualitative assessment of gyral variants in the parietotemporal operculum.**

Results.—**All groups had left-sided asymmetry for the temporal bank and right-sided asymmetry for the parietal bank. The group with dyslexia had exaggerated asymmetries, owing to a significant shift of right planar tissue from the temporal to parietal bank. They also had a higher incidence of cerebral anomalies bilaterally (subjects with dyslexia, six of nine; relatives, two of 10; and controls, zero of 12).**

Conclusions.—**Quantitative assessment of high-resolution magnetic resonance images can reveal functionally relevant variations and anomalies in cerebral structure. Further refinement of these measurement techniques should improve the diagnosis, classification, and treatment of language disorders and other learning disabilities.**

(*Arch Neurol.* 1993;50:461-469)

Dyslexia is a developmental disorder in which children with average or superior intelligence demonstrate a persistent deficit in learning to read, spell, and write.[1] Although it has been proposed that individuals with dyslexia have problems in sequencing streams of information in many modalities,[2-5] most professionals believe that dyslexia results from disordered language processing rather than from visual deficits.[6,7] Individuals with dyslexia have difficulties with phonological decoding of orthographic symbols, and this is a significant source of reading problems. Both readiness to read and later reading competence are strongly related to the development of phonological awareness—the ability to manipulate sounds and segment words into syllables and syllables into phonemes.[8] Although many individuals with dyslexia learn to read well enough to attend college and become successful professionals,[9] many show persistent deficits in phonological awareness.[10] Individuals with dyslexia may suffer other kinds of information-processing deficits as well.[11]

The cortical structures devoted to auditory processing are found in the temporal bank of the sylvian fissure. Heschl's gyrus receives the ascending auditory projections from the medial geniculate and relays them to the secondary auditory cortex of the planum temporale and superior temporal gyrus. This is a site where auditory phonemes could be mapped onto visual graphemes relayed from parieto-occipital cortex. Lateral asymmetries in the size or detail of this map may be associated with the well-documented leftward asymmetry in the temporal bank of the planum.[12,13] The parietal bank of the fissure in the supramarginal gyrus, on the other hand, is normally longer on the right, and this asymmetry may be associated with a right-hemisphere bias for nonverbal or visuospatial processing.[14,15]

Early investigators believed that neuroanatomical cor-

Accepted for publication September 8, 1992.

From the Departments of Neuroscience (Dr Leonard), Psychiatry (Drs Voeller and Morris and Ms Garofalakis), Communication Processes and Disorders (Dr Lombardino), and Radiology (Drs Honeyman, Mao, Agee, and Staab), University of Florida, and the Morris Center (Drs Alexander and Andersen), Gainesville; and the Department of Special Education, University of Georgia, Athens (Dr Hynd).

Reprint requests to Department of Neuroscience, PO Box 100244, University of Florida Health Science Center, Gainesville, FL 32610 (Dr Leonard).

Downloaded from www.archneurol.com at Columbia University, on December 21, 2010

relates of dyslexia would be too subtle to be visible on gross morphological analysis.[16] Drake,[17] however, reported anomalous sulci and gyri in the left parietal operculum of a 12-year-old child with a learning disability who died suddenly. In the late 1970s, Galaburda and coworkers[18,19] began a pioneering series of analyses of the planum in the brains of individuals with dyslexia that were provided by the Orton Society. He and his colleagues have reported on eight brains. All had symmetric plana due to increased size on the right and most showed evidence of migratory abnormalities during neural development.

Two recent magnetic resonance imaging (MRI) studies have confirmed that individuals with dyslexia have symmetrical plana.[20,21] In these studies, however, the symmetry was due to small left plana, rather than to increased size on the right. The two MRI studies imaged the brain in the sagittal and coronal plane, respectively, and identified the planum using anatomical landmarks, but these studies did not distinguish between the temporal and parietal banks of the planum. Other MRI studies using the more traditional axial plane have compared the width or volume of the parieto-occipital cortex in the two hemispheres. These studies have also reported anomalous or reversed symmetry in individuals with dyslexia[22] and children with language disorders.[23-25]

There have been recent dramatic improvements in MRI technology. It is now possible to visualize serial sections of the brain on gapless series of thin sections, using volumetric acquisitions.[26,27] Furthermore, these images have anatomical validity. Measurements of the planum on sagittal images of postmortem specimens correlate highly with planar size measured on photographs of the same specimens.[28]

In the present study, we used a volumetric acquisition to search for anomalies in dyslexia. Measurements of the temporal and parietal banks of the planum temporale and Heschl's gyri were made with a computer-guided cursor. We also categorized the sylvian fissures[29] and looked for evidence of neurodevelopmental perturbations such as duplicated or missing gyri.

Table 1.—Characteristics of Control, Dyslexic, and Relatives Groups*

Family	Case No./Sex/Age, y	LAC	WAS
	Controls		
1	1/F/52	99	106
	2/M/28	NA	117
	3/F/25	NA	105
2	4/M/50	100	122
	5/F/48	100	139
	6/F/14	100	129
3	7/M/50	93	112
	8/F/21	100	112
4	9/F/45	100	109
5	10/M/48	99	102
6	11/F/50	100	139
7	12/M/21	100	112
Mean±SD	. . ./. . ./37.1±13.5	99±2	117±12
	Subjects With Dyslexia		
4	13/M/48	88	95
	14/F/21	94	116
	15/F/15	100	101
5	16/M/15	75	86
6	17/M/50	76	92
8	18/M/25	99	114
10	19/M/35	46	76
11	20/M/48	92	101
12	21/M/65	NA	NA
Mean±SD	. . ./. . ./36.0±17.1	84±17	98±13
	Relatives		
4	22/F/18	94	96
5	23/F/42	91	114
	24/F/12	100	119
	24/M/9	87	118
	26/F/6	58	81
6	27/F/14	99	130
	28/F/12	100	125
8	29/M/56	93	112
	30/M/63	NA	106
9	31/M/21	94	92
Mean±SD	. . ./. . ./25.7±20.3	91±12	109±15

*LAC indicates Lindamood Auditory Conceptualization Test.[30] Adults are expected to score 100%. WAS indicates Word Attack Subtest of the Woodcock Reading Mastery Test, revised[31]; NA, test score not available.

SUBJECTS AND METHODS

Subjects

Subjects for the study consisted of 12 controls (five male and seven female, aged 14 to 52 years); nine individuals with dyslexia (seven male and two female, aged 15 to 65 years); and 10 unaffected relatives of the individuals with dyslexia (four male and six female, aged 6 to 63 years). These subjects were students or were from professional families. All subjects with the exception of one relative (case No. 30) were right-handed. Informed consent was obtained after procedures were explained.

Subjects were assigned to the group with dyslexia on the basis of a diagnosis of dyslexia by a pediatrician, pediatric neurologist, or learning disabilities specialist. The diagnosis was based on a clinical interview, family history, and the results of a test battery. The Lindamood Auditory Conceptualization Test (LAC)[30] and the Word Attack Subtest of the Woodcock Reading Mastery Test, revised version,[31] were used to test phonological decoding skills. In the LAC, subjects demonstrate their ability to manipulate phonemes by rearranging colored blocks that they use to represent the phonemes. No standard scores are available, but adults and children older than 12 are expected to score 100%.[30] In the Word Attack Subtest, subjects pronounce visually presented nonsense words and receive a standard score. All the adult subjects with dyslexia fit the profile of the "recovered dyslexic."[10] They had a family history of dyslexia and reported finding schoolwork arduous due to difficulty with reading but had been able to compensate with memorization and other techniques. None of the subjects with dyslexia reported reading for pleasure but all were functioning well in school or their profession.

Subjects were assigned to the relatives group if they (1) were the first- or second-degree relative of an individual in whom dyslexia was diagnosed; (2) had a family history of dyslexia; but (3) had never received a diagnosis of dyslexia. Subjects were classed as controls if (1) there was no history of reading difficulties in their parents, siblings, nephews, or nieces and (2) they had never been referred for diagnosis or treatment of dyslexia. This group included three spouses of subjects with dyslexia who reported no genetic relatives with a history of dyslexia. Individual characteristics of the subjects are given in Table 1. As can be seen from Table 1, the Word Attack Subtest and LAC scores of the three groups overlapped to some extent. Since some of the subjects with dyslexia had received much more intensive phonological training than subjects in the other groups, we did not use these scores for the assignment of group membership if they conflicted with the evidence from the clinical history.

MRI Scan Acquisition

The scans were performed with a quadrature head coil in a Seimens 1 T Magnetom (Seimens, Iselin, NJ) at the University of Florida Health Science Center, Gainesville. Gapless series of thin

Downloaded from www.archneurol.com at Columbia University, on December 21, 2010

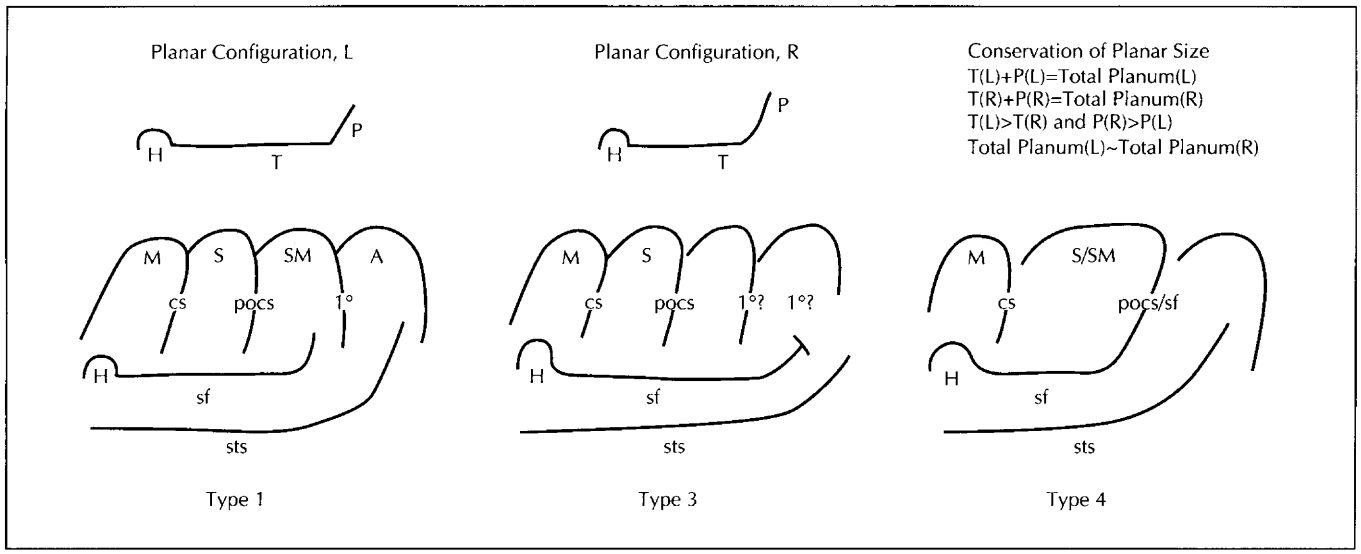

Fig 1.—*Top, A schematic illustration of the relation between the temporal (T) and parietal (P) banks of the planum and the principle of conservation of planar size. Bottom, A schematic diagram of the fissure types found in this study using the Steinmetz et al*[29] *classification scheme. cs indicates central sulcus; pocs, postcentral sulcus; sf, sylvian fissure; sts, superiotemporal sulcus; 1°, primary sulcus; H, Heschl's gyrus; M, motor strip (precentral gyrus); S, sensory strip (postcentral gyrus); SM, supramarginal gyrus; and A, angular gyrus. In type 1, the most common type of fissure, the sf terminates between the pocs and 1°, defining SM; in type 3, the sf does not terminate in a clearly demarcated SM owing to the presence of multiple 1°; and in type 4, the sf fuses with the pocs, resulting in fused or undifferentiated S and SM.*

sagittal sections were obtained with a volumetric acquisition gradient echo sequence. The first 13 subjects (six controls, four with dyslexia, three relatives) to be scanned received a "3-D Flash" sequence with slice thicknesses varying from 1 to 1.17 mm (repetition time, 22 ms; echo time, 6 ms; 50° flip angle; 1 excitation; field of view, 25 cm; 128- to 150-mm excited volume; 256×256 matrix; 128 partitions; 12.03 minutes acquisition time). The images from this sequence varied somewhat in contrast and pixel gray level. The remaining subjects were scanned using a 6-minute "Turboflash" (MPRage) sequence[32] (repetition time, 10 ms; echo time, 4 ms; 10° flip angle; FOV=25.5; 160-mm excited volume; 130×256 matrix; 128 partitions; 1.25-mm slice thickness). This sequence produced artifact-free, high-contrast images.

In the initial 10 scans, an attempt was made to position the subjects in the scanner in a consistent horizontal plane and to reposition the head if there were tilts in the axial or the sagittal plane. These procedures were subsequently discontinued because they lengthened scan time, decreased subject cooperation, and did not result in appreciable improvements in head position. Since volumetric acquisitions can be reformatted in any plane, variations in head position can be compensated for after the scan. For 14 of the subjects (five controls, four with dyslexia, five relatives), an additional axial scan provided traditional T_2 and spin density images that, together with a subset of the sagittal images, were filmed and read by a radiologist "blind" to subject classification. (These scans were all read as normal.)

Scan Transfer and Preliminary Analysis

The sagittal images were transferred over a fiberoptics network (Vortech, Dallas, Tex) to a Sun workstation (Sparcstation 2, Sun Microsystems, Mountain View, Calif), where programs written in C and PV-Wave (Precision Visuals Inc, Boulder, Colo) stripped the headers, reduced the data from 16 to 8 bits per pixel, and placed the images into a single file labeled with an identification (blind) number. This file contained all the sagittal images on which any cerebral cortex could be recognized (about one hundred 65 543–byte images per file). The midline section was identified as the section containing mammillary bodies, optic recess, infundibulum, anterior commissure, posterior commissure, and the greatest expanse of third ventricle. The width of each hemisphere was then calculated by subtracting the midline section number from the last cortical section on each side and multiplying by the section thickness (1.25 mm).

To ensure that comparable regions were examined in each brain, we adopted the Talairach and Tournoux proportional grid method.[33] Part of this procedure involves dividing each hemisphere into four sagittal slabs of equal width by dividing the hemisphere width by four. We defined the width of one of these slabs as a standard unit and made prints of sections at positions between 2.25 to 3.25 standard units in each brain. Since, in this study, the width of individual hemispheres varied between 6.0 and 7.2 cm, a standard unit equaled approximately 1.6 cm or 13 1.25-mm thick sections.

Quantitative Measurements of the Planum

Anatomical Borders.—Since thin sagittal MRI images have only recently become available, there are no standard methods established for defining the origin and termination of anatomically defined structures. We followed common practice and defined the anterior border of the planum as the most anterior Heschl's sulcus.[13-15,28] The posterior termination of the temporal bank of the planum was defined as the bifurcation into a posterior ascending ramus (PAR) and posterior descending ramus. When there was no bifurcation, or no clear origin of a PAR, the junction of the temporal and parietal banks was defined arbitrarily as the point at which a cursor following the plane of the temporal bank intersected the parietal operculum on lateral sections. We measured both the temporal and the parietal banks of the planum and then added them together for a total planum length (Fig 1).

Relation to Previous Work.—Different investigators have made different decisions regarding the borders of the planum in the PAR. Galaburda and his colleagues[34] did not distinguish between the temporal and parietal banks. In Fig 1 of their recent publication reanalyzing the brains studied by Geschwind and Levitsky,[12] the artist's drawing indicates that measurements were made of the temporal bank on the left and the parietal bank on the right. Perhaps this is an artist's error, for the figure indicates that Heschl's gyrus and sulcus on the right side are in the parietal bank, which is not possible, by definition. The investigators report a mean leftward asymmetry, which conflicts with previous reports[14,15] of reversed asymmetry in the parietal bank and symmetry for measurements of the total planum. In the original article of Geschwind and Levitsky,[12] the text as well as the figure imply that measurements were restricted to the temporal bank of the planum on each side. On balance, the evidence suggests that

Downloaded from www.archneurol.com at Columbia University, on December 21, 2010

Geschwind and Levitsky measured the temporal bank because (1) they obtained a significant mean leftward asymmetry and (2) their means match the average values obtained for the length of the lateral edge of the temporal bank of the planum in our sample (C.M.L., unpublished data, 1991).

Sagittal Positions and Asymmetry Coefficients.—The second step in the quantitative analysis was the choice of number and position of sections for measurement. We had originally intended to calculate the area of the temporal planum by measuring the surface of each section and multiplying by the section thickness. However, we found that measurements made on lateral sections tended to be unreliable because (1) Heschl's sulcus disappears on far lateral sections, leaving no clear anterior border for the planum[14,28] and (2) sections taken at the lateral cortical edge had many minor convolutions that are difficult to trace in a repeatable manner. We found that the length of the temporal bank between sagittal positions of 2.75 and 3.25 correlated well with the area but could be measured more reliably. The SD ranged from 2 to 6 mm for averages of measurements on six to eight sections between these two positions.

The advantage of calculating an average length is that the SD of the asymmetry can also be established for each brain. Some previous studies[12,18-21] have used arbitrary criteria (1 to 2 mm or 10%) for asymmetry. The interhemispheric coefficients of asymmetry for the temporal (T), parietal (P), and total planum were calculated using the formula $(L-R)/[(L+R)/2]$. In addition, intrahemispheric coefficients of asymmetry, $(T-P)/[(T+P)/2]$, were calculated for the left and the right hemispheres.

Technical Details

The lengths of the gyral surfaces were measured by adapting the method of Zilles et al[35] in which the tracing follows the exposed surface and does not enter sulci whose walls are tightly opposed. This method was more reliable than alternative procedures that traced the gray-white border or followed every surface irregularity. Measurements were made on the monitor with a mouse-operated cursor. A program written in PV-Wave calculated each segment length and continually added to the surface distance until the signal for measurement termination was given. Means, SDs, and asymmetries were stored in a file that was transferred by network to a spreadsheet. Photographs for illustrations were made by photographing the image displayed on the computer monitor.

Several series of measurements were made on each structure. On a subset of brains, a reliability study was performed by operators who were blind to group membership. If the average measurements did not agree within 10%, the measurements were redone. We eventually developed a set of rules for identifying structure boundaries that included all the variants found in a more extensive series of brains with a variety of diagnoses. This set of rules and the source code for the PV-Wave programs can be obtained from us on request.

Qualitative Analysis

Sylvian Fissure.—We classified the sylvian fissures using a modification of the recently described method of Steinmetz et al.[29] This method, developed with observations on both imaged and postmortem material is a categorical one that uses both the morphologic structure of the sylvian fissure and that of the supramarginal gyrus to assign each fissure to one of four types (types 1, 3, and 4 are illustrated in Fig 1, bottom). Type 1, the one that is most commonly found, terminates in a PAR in the supramarginal gyrus. Type 2 has no PAR, while type 3 is exceptionally long, with an extra supramarginal gyrus. Type 4 is short, and the supramarginal gyrus merges with the postcentral gyrus. Witelson[15] has proposed a similar classification based on examination of postmortem material. We are curently comparing the Steinmetz and the Witelson systems on a larger series of brains.

To categorize the fissures, we paged through each hemisphere from medial to lateral, noting the section on which the PAR began to rise and the location of the primary fissure (which separates the postcentral gyrus from the supramarginal gyrus). The sylvian fissure was classified as type 3 if the presence of multiple primary fissures at sagittal position 3.0 prevented delineation of the supramarginal and angular gyri (Fig 1, bottom).

Heschl's Gyri.—The presence of primary (H1) and (if present) secondary Heschl's gyri (H2) were noted from sagittal positions 2.0 to 3.0. The boundaries of H1 were always clear. The presence of H2 was not as clear, particularly on the right side, where the planum can have an irregular surface. To provide a supplemental quantitative assessment, the surfaces of H1 and H2 were traced on each side between 2.25 and 2.75. If no clear H2 was present, the tracing was terminated at the posterior end of the first irregularity encountered in the surface. The ratio of the surface to the length of the base was calculated for each gyrus. A survey of Heschl's gyri in 40 brains has demonstrated that the H1 ratios are normally distributed. The distribution of H2 ratios, however, was highly skewed because of the large number of values close to 1 (ie, no H2). Those brains with values in the tail of the distribution (ratios >1.3) were ones where a clear Heschl's gyrus was visible from the most medial sections. A ratio of 1.3 was therefore used as a quantitative cutoff criterion in the present study to define the presence of an H2.

Statistical Analysis

The probability that group mean interhemispheric and intrahemispheric coefficients of asymmetry were significantly different from 0.0 (symmetry) was assessed with the means procedure from PC-SAS.[36] Separate repeated-measures analyses of variance were used to test for group differences. The significance of categorical differences between the groups was assessed with Fisher's Exact Probability Test.[37] Since the sex ratios in the different groups were not controlled, we made a preliminary examination of the data to evaluate the presence of sex differences. For each measure, female and male subjects were distributed across the range, and the mean female and male scores did not differ. Similarly, the entire sample was split into young (6 to 28 years) and old (35 to 65 years) halves to ensure that there were no age-related differences in the distribution of any variable.

RESULTS

Interhemispheric Asymmetries

Almost all subjects, regardless of group, demonstrated leftward asymmetry in the temporal bank and rightward asymmetry in the parietal bank (Table 2 and Fig 2). Three controls and one relative had temporal banks with asymmetries small enough to be within the range of measurement error. Only one subject (a right-handed relative) had reversed right-left asymmetry in the temporal bank. All nine subjects with dyslexia had leftward asymmetries in the temporal bank and eight had rightward asymmetry of the parietal bank. When the temporal and parietal banks were summed to give a total planum value, each group had a small but insignificant ($P>.05$) leftward asymmetry.

Intrahemispheric Asymmetries

All subjects, with the exception of two subjects with dyslexia, had larger temporal than parietal banks in the left hemisphere (Fig 2), with highly significant mean intrahemispheric coefficients of asymmetry (Table 2). There was, however, a significant difference between the groups in the right hemisphere, where five of nine subjects with dyslexia and four of 10 relatives had larger parietal than temporal banks. Neither the relative nor the group with dyslexia had a significant mean intrahemispheric asymmetry on the right side. A repeated-measures analysis of variance on the intrahemispheric coefficients of asymmetry showed that the group difference was significant

Downloaded from www.archneurol.com at Columbia University, on December 21, 2010

Table 2.—Average Length of Temporal and Parietal Banks of Planum and Interhemispheric and Intrahemispheric Coefficients of Asymmetry in Controls, Dyslexic Subjects, and Nonaffected Relatives of Dyslexic Subjects*

	Temporal Bank			Parietal Bank			Intrahemispheric CoTP	
Group	L, cm	R, cm	Interhemispheric CoLR, %	L, cm	R, cm	Interhemispheric CoLR, %	L (CoTP)	R (CoTP)
Controls (n=12)	3.2±0.6	2.7±0.4	17±22†	1.0±0.7	1.2±0.7	−18±41	108±50‖	81±51§
Dyslexics (n=9)	2.9±0.9	1.9±1.0	48±25§	0.9±0.6	1.7±0.7	−67±50‡	101±74‡	2±86
Relatives (n=10)	3.2±0.5	2.2±0.9	40±34‡	1.2±0.5	1.8±0.7	−45±56†	98±38‖	19±63

*The mean for each group represents an average of six to eight sections through the planum in each individual; values are given as mean±SD; interhemispheric coefficient of asymmetry (CoLR)=(L−R)/[(L+R)/2]; intrahemispheric coefficient of asymmetry temporal and parietal (CoTP)=(T−P/[T+P)/2].

†Asymmetry significantly different from 0.0, $P<.05$.

‡Asymmetry significantly different from 0.0, $P<.01$.

§Asymmetry significantly different from 0.0, $P<.001$.

‖Asymmetry significantly different from 0.0, $P<.0001$.

($F[2,28]=4.67$, $P<.02$), with a post hoc Duncan test showing that the controls and subjects with dyslexia (but not the relatives) differed at the .05 level. Thus, the subjects with dyslexia had reduced right intrahemispheric coefficients of asymmetry due apparently to the transfer of planar tissue from the temporal to the parietal bank (Table 2 and Fig 2), a right parietal shift.

Figure 3 illustrates two extreme cases of parietal shift. The sections are from the most lateral image measured on the left and the right in two subjects with dyslexia. Even in these lateral images, where the planum normally reaches its greatest extent, the temporal bank of the planum is very short. In the image shown on the lower right, Heschl's sulcus is equivalent to the posterior descending ramus. The arrowhead indicates the junction between the (missing) temporal bank and the parietal bank. In these two cases with short temporal plana, the parietal lobes posterior to the parietal bank are highly convoluted with clear primary and secondary sulci, in contrast to the parietal lobes with type 3 fissures, discussed below. This configuration has been called V-type by Witelson[15] because of the disproportionate size of the vertical (parietal) bank of the planum.

Quantitative Analysis

Sylvian Fissures.—In the controls, the left sylvian fissure typically ended in a bifurcation[38,39] into small ascending and descending branches (top left, Fig 4). In some cases there was no bifurcation. The PAR simply ascended from a clearly defined origin (top right, Fig 4). In both these variants, the ascending ramus entered a supramarginal gyrus whose posterior border was a single, well-defined primary ramus (the criterion for a type 1 sylvian fissure). Eleven of 12 controls had type 1 fissures on the left. In six of nine brains of the subjects with dyslexa and in four of 10 brains of the relatives, however, there was no clear primary fissure. Rather, there were extra gyri in the parietal operculum anterior to the termination of the sylvian fissure (asterisks in Fig 4, bottom). This pattern meets the Steinmetz definition of a type 3 fissure. The difference between the proportion of type 3 fissures in the subjects with dyslexia and the controls was significant (Fisher's Exact Probability Test, $P=.025$).

Overall, the distributions of type 1 (67%) and type 3 (33%) fissures were comparable with those reported previously.[29] The proportion of type 1 fissures on the left was larger than would be expected in the controls (90% vs 67%) and smaller in the subjects with dyslexia and relatives (52%). As no behavioral data were available in the previous study, it is possible that type 3 fissures in that population could have been from families with learning disabilities.

Multiple Heschl's Gyri.—A comparison of the appearance of single and multiple Heschl's gyri on three equally spaced sagittal sections of two left hemispheres is illustrated in Fig 5. In the control case, one Heschl's gyrus was clearly visible on the most medial section. On more lateral sections, Heschl's gyrus moved anteriorly and dissolved into a number of convolutions in the superior temporal gyrus. In the subject with dyslexia, there were two Heschl's gyri on the most medial section. The more anterior Heschl's gyrus (H1) separated and moved anteriorly in the lateral sections, while H2 remained fixed.

Duplicate Heschl's gyri were clearly distinguishable in the left hemisphere of two subjects with dyslexia and one relative. On the right side, the planum was more irregular and it was necessary to resort to a quantitative cutoff criterion to separate a population of cases with an H2 (see explanation in "Subjects and Methods" section). Multiple Heschl's gyri on the right, defined using this criterion, were found in three subjects with dyslexia (one case was bilateral). In each of the cases defined by this criterion, an H2 that resembled a miniature version of the H1 was visible on medial sections.

Summary

The cerebral anomalies found in each case are given in Table 3. Three anomalies were defined: (1) parietal shift (negative or reversed intrahemispheric coefficients of asymmetry; n=12; two left, 10 right); (2) a type 3 or 4 sylvian fissure (n=13); and (3) multiple Heschl's gyri (n=6). Every subject with dyslexia had at least one anomaly and six had bilateral anomalies (10 on the left and nine on the right). Seven of the 10 relatives had anomalies (five on the left and five on the right) but only two had bilateral anomalies. Two controls had unilateral anomalies (one on the left and one on the right). The subjects with dyslexia had a significantly greater proportion of bilateral anomalies than the controls (Fisher's Exact Probability Test, subjects with dyslexia vs controls, $P<.01$).

Because impaired phonological decoding may be a defining deficit for dyslexia, it was of interest to look at the relation between phonological test score and the morpho-

Downloaded from www.archneurol.com at Columbia University, on December 21, 2010

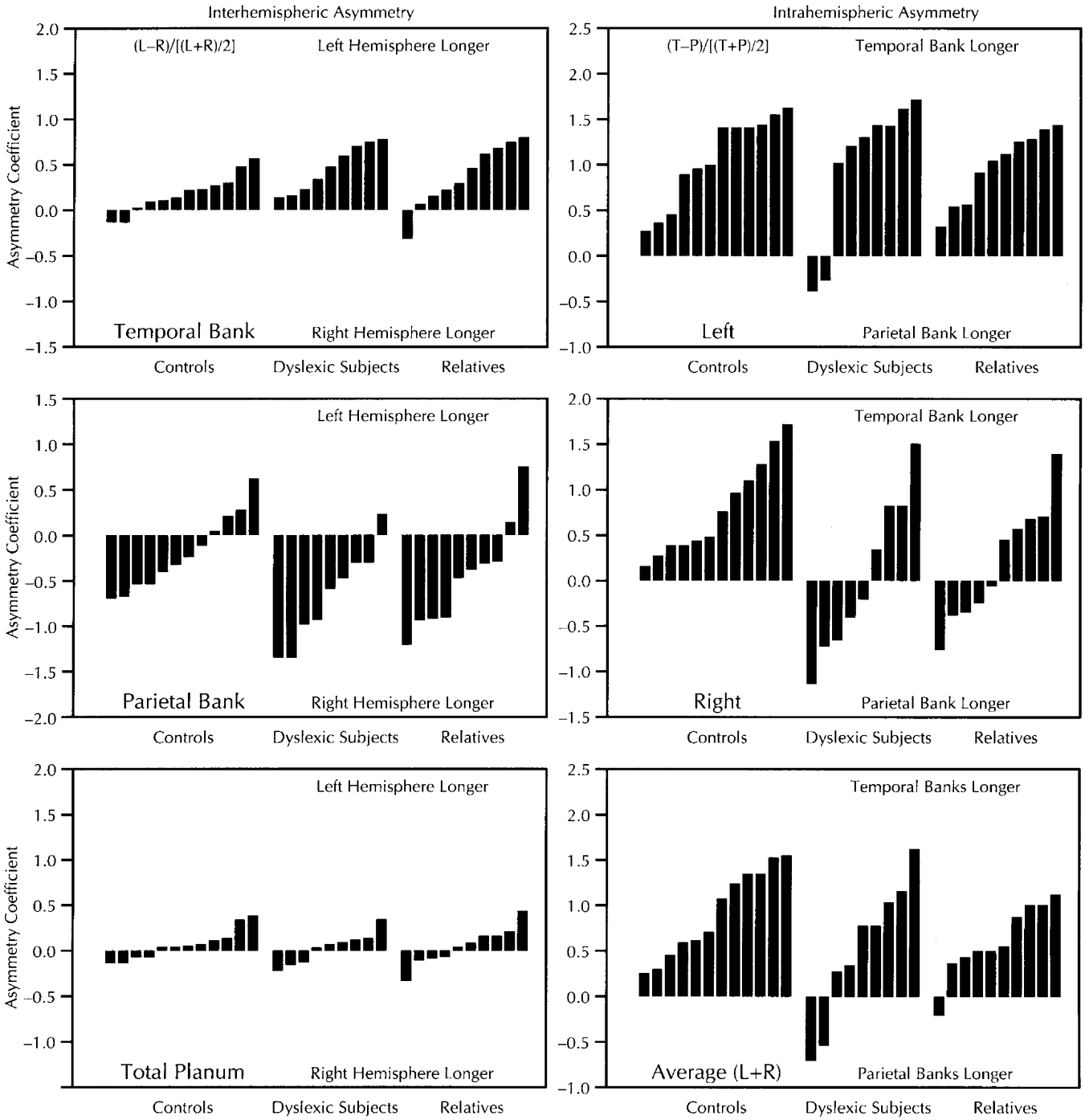

Fig 2.—*A comparison of interhemispheric and intrahemispheric asymmetries in the planum. In each graph, the values have been arranged in order of increasing size for each group. In formulas, T indicates temporal; P, parietal.*

logic structure of the brain regardless of diagnostic category (Table 4). The subjects were divided into three approximately equal-sized groups with low, intermediate, and high LAC or Word Attack Subtest scores and the proportion of bilateral anomalies in each group compared. No one with a perfect LAC score had a bilateral anomaly, while such anomalies were characteristic of half the subjects in the groups with low and intermediate scores. The relationship between cerebral structure and the Word Attack Subtest was less strong. Interestingly, clinical diagnosis was as good a predictor of the presence of bilateral anomalies as the objective test scores.

COMMENT

There were three major findings. (1) The subjects with dyslexia in this study did not have anomalous interhemispheric symmetry in the temporal bank of the planum, the part of the planum where leftward asymmetry correlates with functional localization for language.[14,15,40] In fact, the group with dyslexia had an exaggerated mean leftward asymmetry in this bank. (2) Some subjects with dyslexia did, however, have an anomalous intrahemispheric asymmetry between the temporal and planar banks in the right hemisphere due to an increased proportion of planar tissue in the parietal bank or a right parietal shift. (3) The

Downloaded from www.archneurol.com at Columbia University, on December 21, 2010

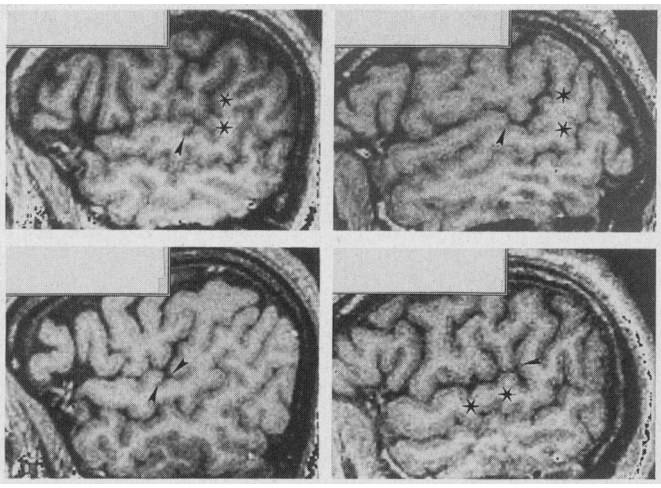

Fig 3.—*Magnetic resonance images of two subjects with dyslexia (left and right) with short temporal banks and long parietal banks in both left and right plana. Arrowheads mark Heschl's sulcus. Top, Left hemisphere. Both subjects have extra gyri in the parietal bank of the planum (asterisks). Bottom, Right hemisphere: patient at left has an extra gyrus in the parietal bank and a short temporal bank (arrowheads). In patient at right, asterisks denote a large Heschl's gyrus in the region normally occupied by the temporal bank of the planum.*

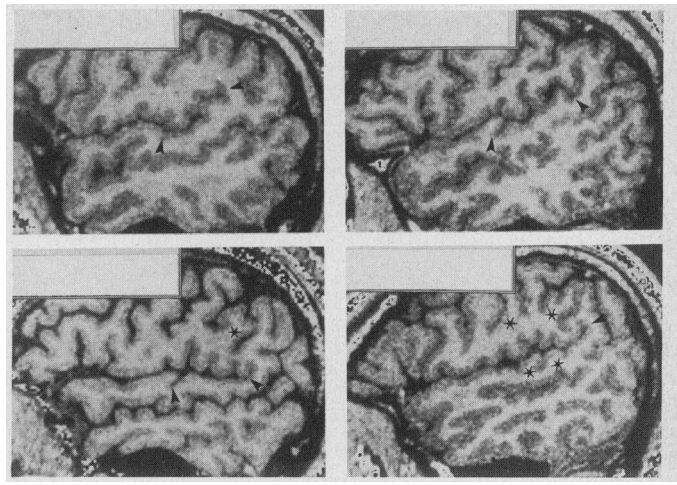

Fig 4.—*Magnetic resonance images of two controls (top) and two subjects with dyslexia (bottom) at sagittal position 3. The controls have either the typical bifurcation (left) or an ascending parietal bank (right) that enters a clearly demarcated supramarginal gyrus. Arrowheads mark the borders of the temporal bank of the planum. The two subjects with dyslexia have type 3 fissures with multiple primary sulci and extra gyri in the parietal operculum (asterisks) and/or multiple Heschl's gyri (asterisks in lower right).*

subjects with dyslexia were also more likely to have cerebral anomalies such as missing or duplicated gyri bilaterally in the planum and parietal operculum. These anomalies may reflect disorders in cell migration resulting from genetic or developmental causes.[41]

Symmetry or Asymmetry?

The first finding was unexpected. An impressive body of literature has accumulated in the past decade suggesting that brains in individuals with dyslexia are anomalously symmetrical. The left posterior bulge is less pronounced or absent on computed tomography and MRI scans taken in the axial plane,[20] while the planum has been found to be symmetrical on postmortem and MRI studies.[18,21] Technical differences in our study design, scan methods, and anatomical nomenclature may explain the discrepancy.

Study Design.—A recent review on brain asymmetry and dyslexia[1] has pointed out that many studies have failed to include a control group but have relied, instead, on published asymmetries obtained on unselected samples of postmortem material or computed tomographic scans that may include subjects with learning disabilities.

Scan Method.—Most previous studies were not able to visualize the planum directly but instead measured the width of a single, thick axial section presumed to include the planum. Intraindividual scan-rescan reliability of such measures is reportedly low.[42] Magnetic resonance imaging studies that have measured the planum have used thick sections or the coronal plane. Perisylvian structures are most clearly visualized on gapless series of thin sagittal images.

Anatomical Nomenclature.—In postmortem studies, both the parietal and temporal banks have been included in the measurement of the planum. Symmetry, due to an enlarged right planum, was found in the brains of eight subjects with dyslexia.[18,19] We also found that the total planum was symmetrical in subjects with dyslexia. However, this symmetry did not distinguish the subjects with dyslexia from the controls or the unaffected relatives. All

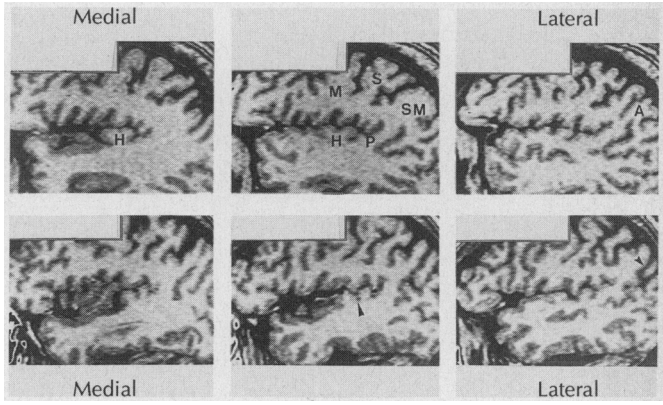

Fig 5.—*Magnetic resonance images of a control (top) and a subject with dyslexia (bottom) at three sagittal positions between 2.25 and 2.75. The dyslexic brain has two Heschl's gyri (H) as well as a type 3 fissure on the left. SM indicates supramarginal gyrus.*

groups demonstrated symmetry when the planum was defined in this way, as reported by other groups.[14,15] Galaburda and his colleagues[18,19] were, however, correct in drawing attention to the right planum of individuals with dyslexia. In our sample, a significantly larger proportion of the right planum was shifted from the temporal to the parietal bank than in controls or unaffected relatives.

Relation Between Brain Structure and Clinical Diagnosis

A prevailing theme in the dyslexia literature has been the search for classification variables. In our study, we deliberately cast a wide net, in the hopes of finding a range of cerebral anomalies that might characterize different diagnostic subgroups. We also scanned as many unaffected relatives as were available, to check if the anomalies found were specific for the expression of dyslexia, or simply an irrelevant family characteristic.

Three cerebral patterns were present with higher frequency in families with dyslexia than in control families: (1) a parietal shift of tissue in the right planum; (2) type 3

Downloaded from www.archneurol.com at Columbia University, on December 21, 2010

Table 3.—Summary of Findings in the Control Group*

Family	Case	Anomalies L	Anomalies R	No. of Anomalies L	No. of Anomalies R	Bilateral
			Controls			
1	1	...	...	0	0	No
	2	...	...	0	0	No
	3	SF=3	...	1	0	No
2	4	...	...	0	0	No
	5	...	...	0	0	No
	6	...	...	0	0	No
3	7	...	...	0	0	No
	8	...	...	0	0	No
4	9	...	...	0	0	No
5	10	...	...	0	0	No
6	11	...	...	0	0	No
7	12	...	SF=4	0	1	No
			Subjects With Dyslexia			
4	13	SF=3, MH	...	2	0	No
	14	SF=3	P>T	1	1	Yes
	15	SF=3	...	1	0	No
5	16	...	MH	0	1	No
6	17	P>T	P>T	1	1	Yes
8	18	SF=3	MH	1	1	Yes
10	19	SF=3, MH	SF=4, P>T, MH	2	3	Yes
11	20	P>T	P>T	1	1	Yes
12	21	SF=3	P>T	1	1	Yes
			Relatives			
4	22	SF=3, MH	...	2	0	No
5	23	...	P>T	0	1	No
	24	SF=3	...	1	0	No
	25	SF=3	P>T	1	1	Yes
	26	...	...	0	0	No
6	27	...	P=T	0	1	No
	28	...	...	0	0	No
	29	...	...	0	0	No
	30	...	P>T	0	1	No
9	31	SF=3	P>T	1	1	Yes

*SF indicates sylvian fissure (type 3 or 4); P, parietal bank; T, temporal bank; and MH, multiple Heschl's gyri.

fissures on the left; and (3) multiple Heschl's gyri on both left and right. The relatives were intermediate between the subjects with dyslexia and controls in both the frequency of cerebral anomalies and level of phonological awareness. The correlation between anatomical and behavioral markers suggests that there is more than just a chance association. Perhaps each type of anomaly is associated with a particular type of information processing or perceptual strategy. Subjects with one anomaly may be able to compensate for their deficit by using alternate strategies. When the anomalies are multiple and bilateral, however, the chance of being able to compensate decreases, increasing the risk of school problems and a diagnosis of learning disability. In the future, MRI scanning should be combined with behavioral instruments designed to assess specific cognitive and perceptual functions. Such an approach might demonstrate that different patterns of cerebral

Table 4.—Distribution of Bilateral Anomalies as Function of LAC Score, Word Attack Subtest Score, and Diagnosis*

	Bilateral Anomalies	No Bilateral Anomalies	Total
LAC score (n=27)			
<93	4	4	**8**
93-99	3	6	**9**
100	0	10	**10**
Total	**7**	**20**	**27**
Word Attack Subtest score (n=30)			
76-101	4	5	**9**
102-112	0	10	**10**
113-139	3	8	**11**
Total	**7**	**23**	**30**
Diagnosis			
+	6	3	**9**
−	2	20	**22**
Total	**8**	**23**	**31**

*LAC indicates Lindamood Auditory Conceptualization Test.[30]

structure are associated with different perceptual or cognitive capacities and strengths. Anecdotal evidence from two cases is presented below to support this possibility.

Parietal Shift and Visuospatial Function.—Only two subjects had larger temporal than parietal banks on the left. These two subjects also had large parietal banks on the right (Fig 3). Both are dyslexic but successful members of professions that require highly developed visuospatial abilities, abilities thought to be dependent on the integrity of the parietal lobe.[43] A parietal shift may reflect an exceptional development of visuospatial ability at the expense of phonological decoding or other language skills. There is considerable experimental evidence to support the role of the parietal lobe in visuospatial processing. For example, neurophysiological studies in nonhuman primates have revealed that the parietal lobe contains multiple repeated "visual maps," ie, complete representations of the visual field devoted to coding a particular visual attribute or function.[44] The size of any particular cortical representation is proportional to the precision and resolution of the map. Expansion of the parietal lobe through genetic or developmental mechanisms would facilitate the growth of expanded, and thus more precise, visual maps. This hypothesis could be tested by determining whether the degree of parietal shift is correlated with visuospatial ability.

Sex Differences.—It has frequently been suggested that dyslexia is more frequent in males. In our unselected sample of subjects with dyslexia, 80% were male, while in the relatives group, 60% were female. We could examine the question of differential vulnerability in four affected families in which three or more members underwent scanning. In these families, one of seven female subjects and three of seven male subjects had bilateral anomalies. The only female with bilateral anomalies was dyslexic. The difference in these ratios is too small to be significant, but it is probably worth investigating whether bilateral anomalies are less frequent in females and, as a result, they are at less risk for dyslexia.

Our findings suggest that the evaluation and measurement of the morphologic features of the brain may eventually be a significant aid to the clinician. It is important, in this regard, to emphasize that none of the observations

Downloaded from www.archneurol.com at Columbia University, on December 21, 2010

made in the present study could have been accomplished on traditional thick sections obtained in the axial plane. Although our data were obtained in a way that enabled three-dimensional reconstruction, we did not have the resources to perform this elaborate and time-consuming procedure. It turned out, however, that the cortical anomalies were better visualized in thin sagittal sections located some distance internal to the lateral surface than they were in surface renderings. We join with other groups[26,27] to urge investigators interested in correlating cerebral structure and behavior to acquire their data in thin serial sections, to test the validity of the findings and interpretations presented herein.

We are deeply grateful to Mary Ellen Bentham and the staff of the Shands Hospital MRI facility, Gainesville, Fla, for their help in obtaining and transfering the scans; to Sam Browd, Melissa Mahoney, Dan Williams, MS, D. J. Williamson, PhD, Paul Moberg, PhD, William Billett, MD, Jose Zayas, Jane Mutch, MA, Frank de Filippo, MA, and Michelle DeCecco for their patience in developing and performing the measurements; to P. V. Rao, PhD, for statistical assistance; and to the staff of the Woods Hole (Mass) Educational Association, Terry Jernigan, PhD, Helmuth Steinmetz, MD, and Kenneth M. Heilman, MD, for invaluable education and encouragement.

References

1. Hynd GW, Semrud-Clikeman M. Developmental dyslexia. *Psychol Bull.* 1989;106:447-482.
2. Stark RE, Tallal P. *Language, Speech and Reading Disorders in Children: Neuropsychological Studies.* Austin, Tex: Pro-Ed; 1988.
3. Lovegrove W, Martin F, Slaghuis W. A theoretical and experimental case for a visual deficit in specific reading disability. *Cogn Neuropsychol.* 1985;3:225-267.
4. Schwartz J, Tallal P. Rate of acoustic change may underlie hemispheric specialization for speech perception. *Science.* 1980;207:1380-1381.
5. Wolff PH, Michel GF, Ovrut M. The timing of syllable repetitions in developmental dyslexia. *J Speech Hearing Res.* 1990;33:281-289.
6. Tallal P. Back to the future: research on developmental disorders of language. In: Miller J, ed. *Research on Child Language Disorders: A Decade of Progress.* Austin, Tex: Pro-Ed; 1991:399-407.
7. Bruck M. Persistence of dyslexics' phonological awareness deficits. *Dev Psychol.* 1992;28:874-886.
8. Gowasmi U, Bryant P. *Phonological Skills and Learning to Read.* Hillsdale, NJ: Lawrence Erlbaum Associates Inc; 1990.
9. Pompian NW, Thun CP. Dyslexic/learning disabled students at Dartmouth College. *Ann Dyslexia.* 1988;38:276-284.
10. Kitz WR, Tarver SG. Comparison of dyslexic and nondyslexic adults on decoding and phonemic awareness tasks. *Ann Dyslexia.* 1989;39:196-205.
11. Kinsbourne M, Rufo DT, Gamzu E, Palmer RL, Berliner AK. Neuropsychological deficits in adults with dyslexia. *Dev Med Child Neurol.* 1991; 33:763-775.
12. Geschwind N, Levitsky W. Human brain: left-right asymmetries in temporal speech region. *Science.* 1968;161:186-187.
13. Witelson SF. Bumps on the brain: right-left anatomic asymmetry as a key to functional lateralization. In: Segalowitz S, ed. *Language Functions and Brain Organization.* Orlando, Fla: Academic Press Inc; 1982:117-144.
14. Steinmetz H, Rademacher J, Jancke L, Huang Y, Thron A, Zilles K. Total surface of temporoparietal intrasylvian cortex: diverging left-right asymmetries. *Brain Lang.* 1990;39:357-372.
15. Witelson SF, Kigar DL. Sylvian fissure morphology and asymmetry in men and women: bilateral differences in relation to handedness in men. *J Comp Neurol.* 1992;323:326-340.
16. Orton S. Word-blindness in school children. *Arch Neurol Psychiatry.* 1925;14:581-625.
17. Drake WE. Clinical and pathological findings in a child with a developmental learning disability. *J Learning Disabil.* 1968;1:486-502.
18. Galaburda AM, Sherman GF, Rosen GD, Aboitiz F, Geschwind N. Developmental dyslexia: four consecutive cases with cortical anomalies. *Ann Neurol.* 1985;18:222-223.
19. Galaburda AM. Ordinary and extraordinary brain development: anatomical variation in developmental dyslexia. *Ann Dyslexia.* 1989;39:67-79.
20. Hynd GW, Semrud-Clikeman M, Lorys AR, Novey ES, Eliopulos D. Brain morphology in developmental dyslexia and attention deficit disorder/hyperactivity. *Arch Neurol.* 1990;47:919-926.
21. Larsen JP, Hoien T, Lundberg I, Odegaard H. MRI evaluation of the size and symmetry of the planum temporale in adolescents with developmental dyslexia. *Brain Lang.* 1990;39:289-301.
22. Hier DB, LeMay M, Rosenberger PB, Perlo VP. Developmental dyslexia. *Arch Neurol.* 1978;35:90-92.
23. Jernigan TL, Hesselink JR, Sowell E, Tallal PA. Cerebral structure on magnetic resonance imaging in language and learning-impaired children. *Arch Neurol.* 1991;48:539-545.
24. Plante E, Swisher L, Vance R, Rapcsak S. MRI findings in boys with specific language impairment. *Brain Lang.* 1990;40:52-66.
25. Duara R, Kushch A, Gross-Glenn K, et al. Neuroanatomic differences between dyslexic and normal readers on magnetic resonance imaging scans. *Arch Neurol.* 1991;48:410-416.
26. Filipek PA, Kennedy DN, Caviness VS, Rossnick SL, Spraggins TA, Starewicz PM. Magnetic resonance imaging-based brain morphometry: development and application to normal subjects *Ann Neurol.* 1989;25:61-67.
27. Damasio H, Frank R. Three-dimensional in vivo mapping of brain lesions in humans. *Arch Neurol.* 1992;49:137-143.
28. Steinmetz H, Rademacher J, Huang Y, et al. Cerebral asymmetry: MR planimetry of the human planum temporale. *J Comput Assist Tomogr.* 1989; 13:996-1005.
29. Steinmetz H, Ebeling U, Huang Y, Kahn T. Sulcus topography of the parietal opercular region: an anatomic and MR study *Brain Lang.* 1990;38: 515-533.
30. Lindamood CH, Lindamood PC. *Lindamood Auditory Conceptualization Test.* Boston, Mass: Teaching Resources Corp; 1971.
31. Woodcock RW. *Woodcock Reading Mastery Tests, Revised.* Circle Pines, Minn: American Guidance Service; 1987.
32. Mugler JP III, Brookeman JR. Three-dimensional magnetization-prepared rapid gradient-echo imaging 3D MP RAGE. *Magn Reson Med.* 1990;15:152-157.
33. Talairach J, Tournoux P. *Coplanar Stereotaxic Atlas of the Human Brain.* Stuttgart, Germany: George Thieme Verlag; 1988.
34. Galaburda AM, Corsiglia J, Rosen GD, Sherman GF. Planum temporale asymmetry, reappraisal since Geschwind and Levitsky. *Neuropsychologia.* 1987;25:853-868.
35. Zilles K, Armstrong E, Schleicher A, Kretschmann HJ. The human pattern of gyrification in the cerebral cortex. *Anat Embryol.* 1988;179:173-179.
36. *SAS/STAT Guide for Personal Computers, Version 6.* Cary, NC: SAS Institute; 1985.
37. Siegel S. *Nonparametric Statistics for the Behavioral Sciences.* New York, NY: McGraw-Hill International Book Co; 1956.
38. Rubens AB, Mahwold MW, Hutton JT. Asymmetry of the lateral sylvian fissures in man. *Neurology.* 1976;26:620-624.
39. Musiek FE, Reeves AG. Asymmetries of the auditory areas of the cerebrum. *J Am Acad Audiol.* 1990;1:240-245.
40. Foundas A, Leonard CM, Heilman KM. Plana asymmetry predicts language lateralization: a correlated Wada and MR study. *J Clin Exp Neuropsychol.* In press.
41. Rakic P. Defects of neuronal migration and the pathogenesis of cortical malformations. *Prog Brain Res.* 1988;73:15-37.
42. Chu CC, Damasio H, Tranel D. Intrasubject correlations of occipital asymmetry measurements based on CT and MRI. *Soc Neurosci Abstr.* 1991; 17:867.
43. Heilman KM, Valenstein E. *Clinical Neuropsychology.* New York, NY: Oxford University Press Inc; 1985.
44. Allman J. Maps in context: Some analogies between visual cortical and genetic maps. In: Vaina L, ed. *Matters of Intelligence.* Dordrecht, the Netherlands: D Reidel; 1987:369-393.

Downloaded from www.archneurol.com at Columbia University, on December 21, 2010